

This talk was presented 26 June 2008,
at the 22nd International Congress and Exhibition
of Computer Assisted Radiology and Surgery,
in Barcelona at the Hotel Constanza from June 25 to 28, 2008.
See <http://kochanski.org/gpk/papers/2008/CarsTalk.html> for the abstract
and <http://kochanski.org/gpk/papers/2008/CarsTalk.pdf> for this set of slides.

Image quality in non-gated versus gated reconstruction of tongue motion using Magnetic Resonance Imaging: A comparison using automated image processing

Greg Kochanski, Christopher Alvey, Christina
Orphanidou, John Coleman, A. McIntyre, and Steven
Golding

University of Oxford Phonetics Laboratory,
Nuffield Department of Surgery, University of Oxford,
and the John Radcliffe Hospital, Oxford, UK.

Image quality in
non-gated vs. gated
reconstruction of tongue motion:
automated image processing

Christopher Alvey, Christina Orphanidou, John Coleman,
A. McIntyre, Steven Golding and Greg Kochanski

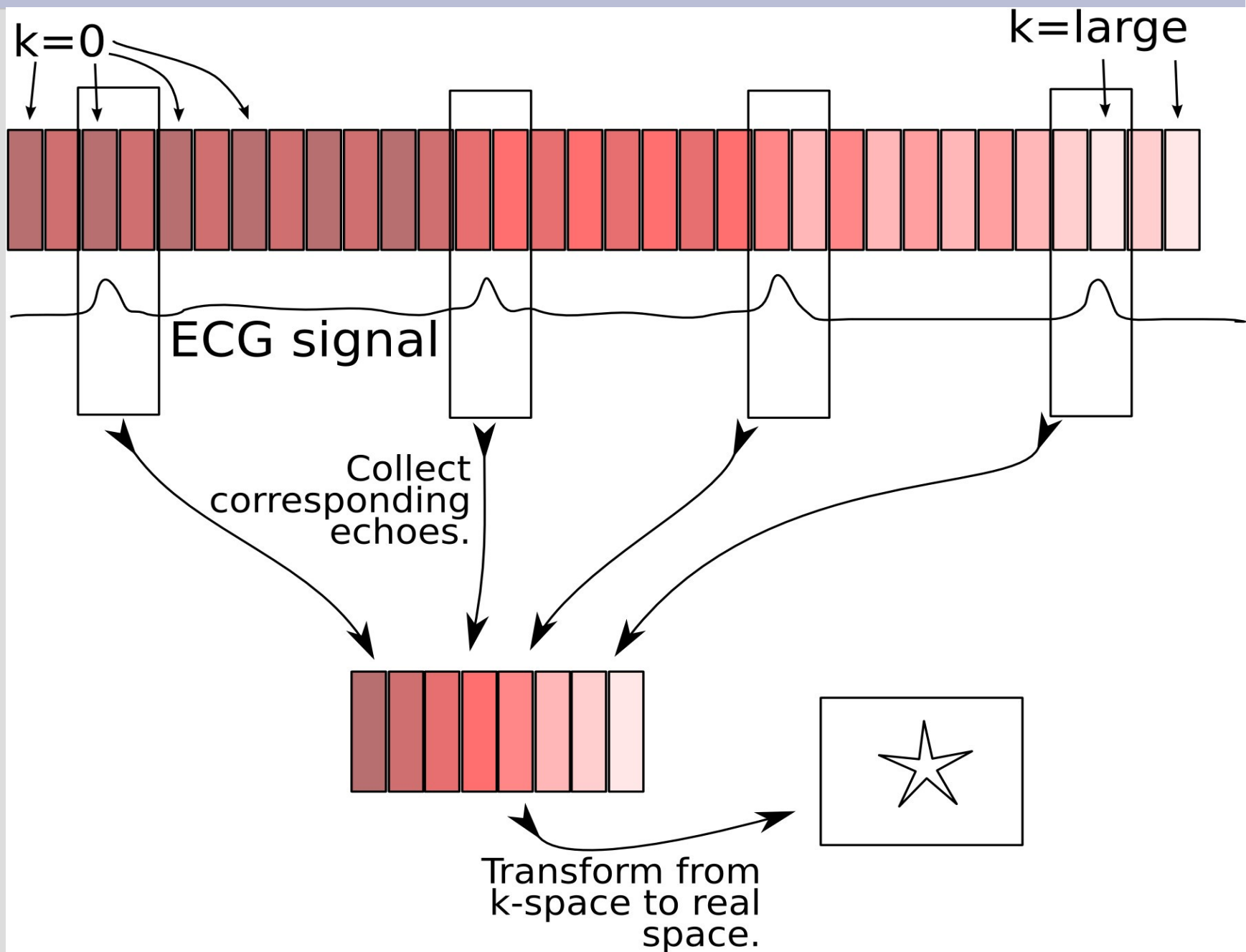
University of Oxford Phonetics Laboratory
Nuffield Department of Surgery, University of Oxford
John Radcliffe NHS Trust

Watching tongues wiggle.

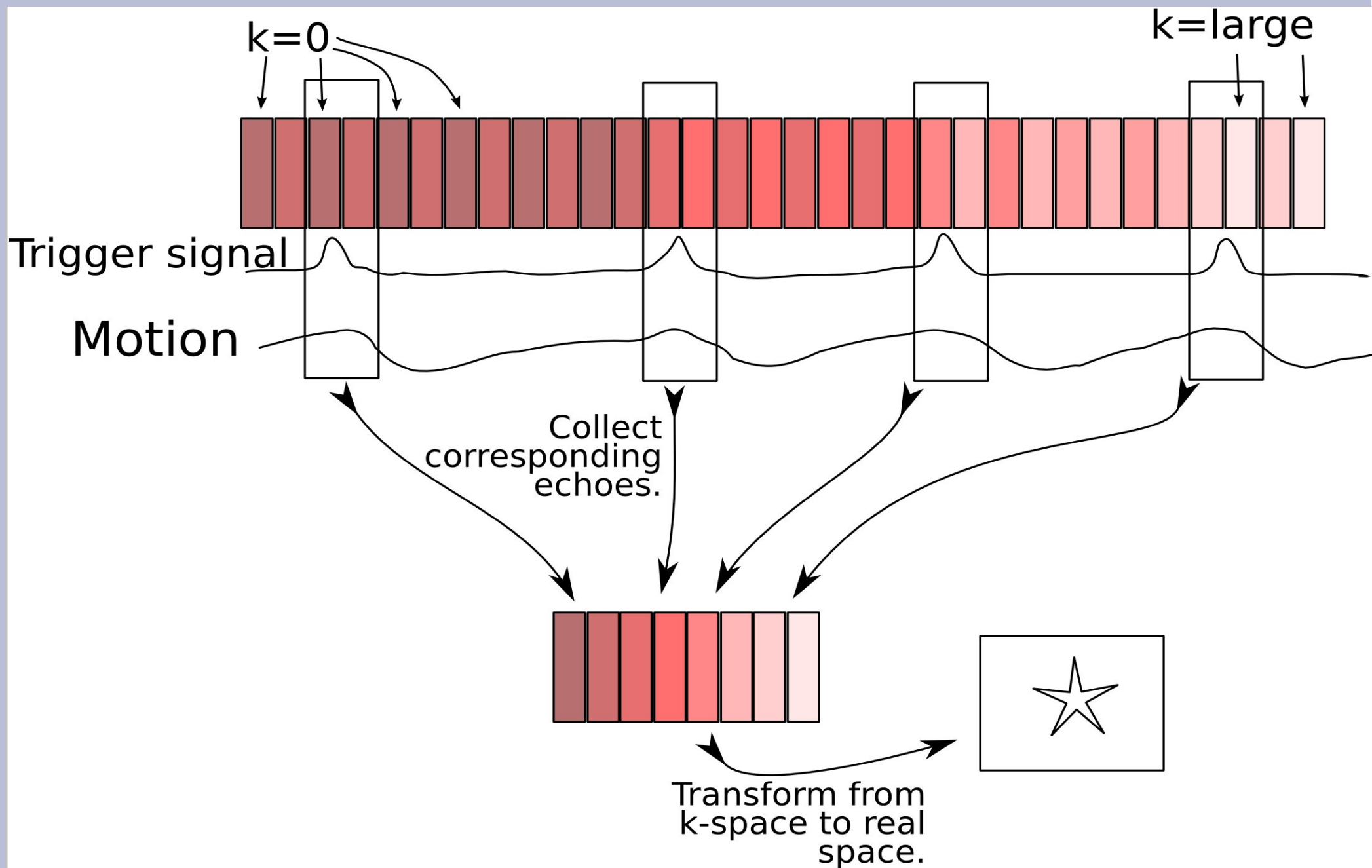
Christopher Alvey, Christina Orphanidou, John Coleman,
A. McIntyre, Steven Golding and Greg Kochanski

University of Oxford Phonetics Laboratory
Nuffield Department of Surgery, University of Oxford
John Radcliffe NHS Trust

Review of gated MRI reconstruction - ideal



Review of gated MRI reconstruction - real



Research Questions

- Are voluntary motions be reproducible enough for gated imaging to work well?
 - Tongue?
- Can we automate image quality assessment?

The apparatus

Under the Desk

Intercom

Metronome computer

Optical Fibre

Photo-diode

MRI machine
ECG inputs

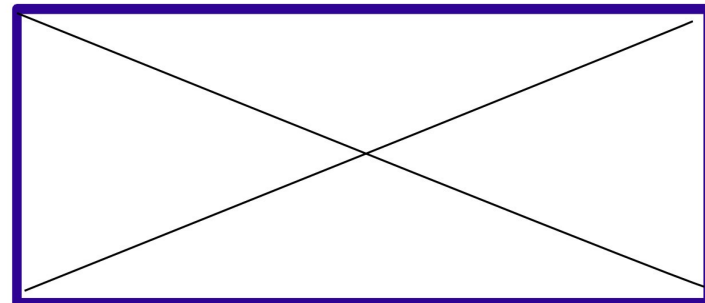
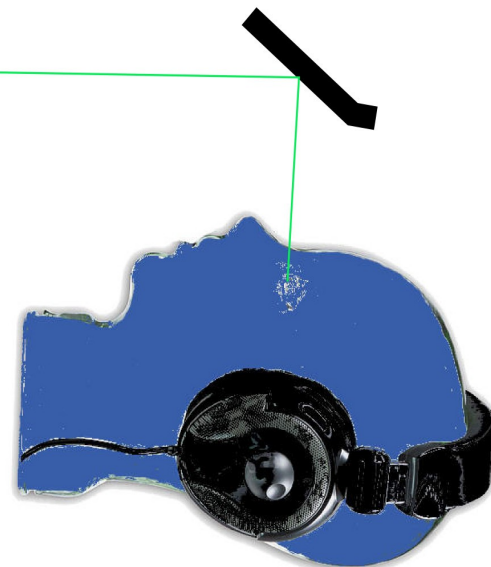
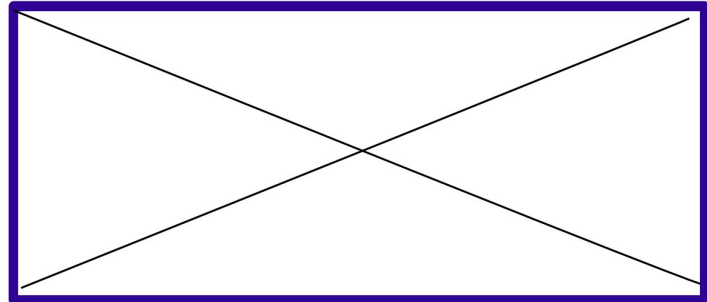


Image Processing Strategy

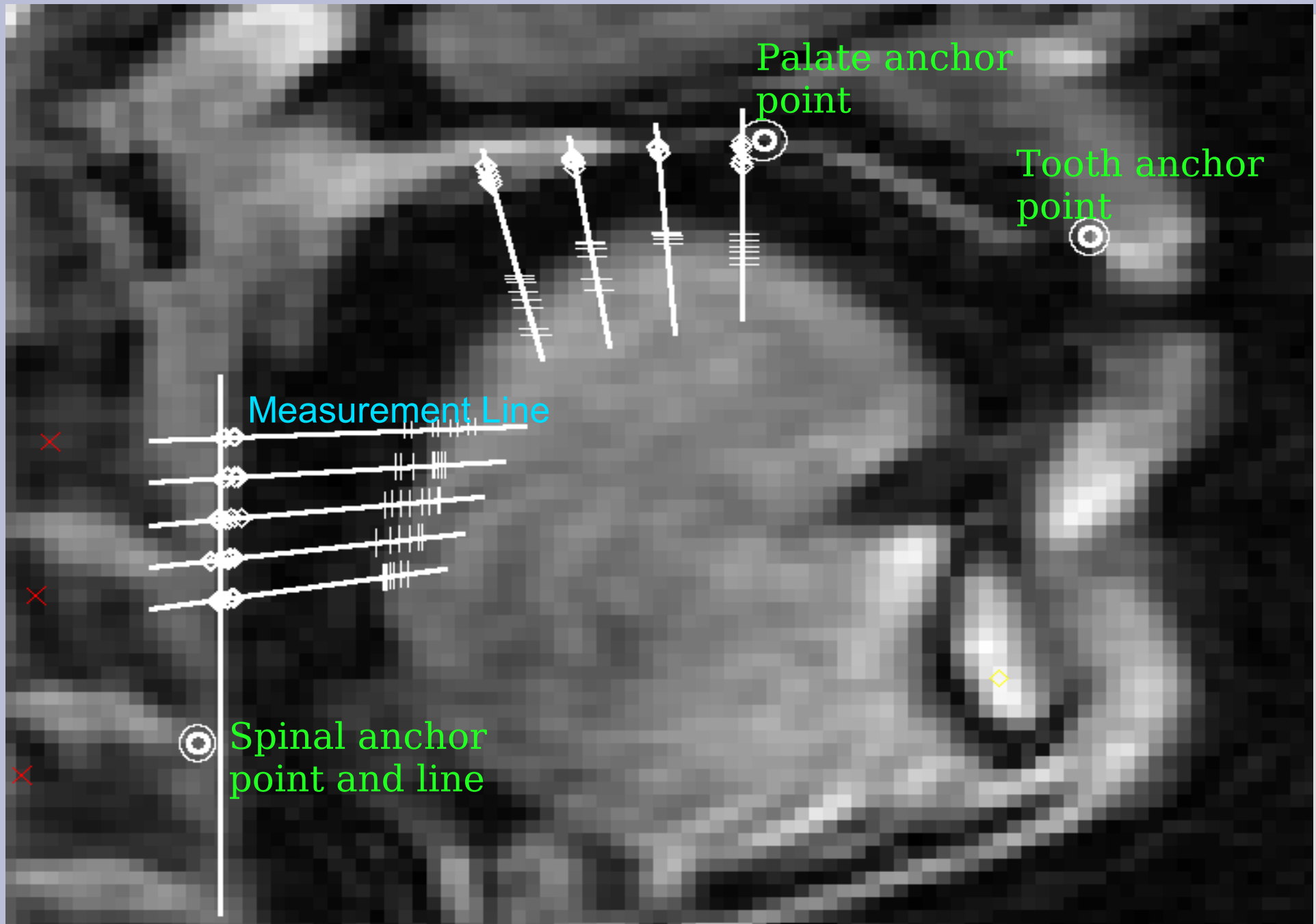
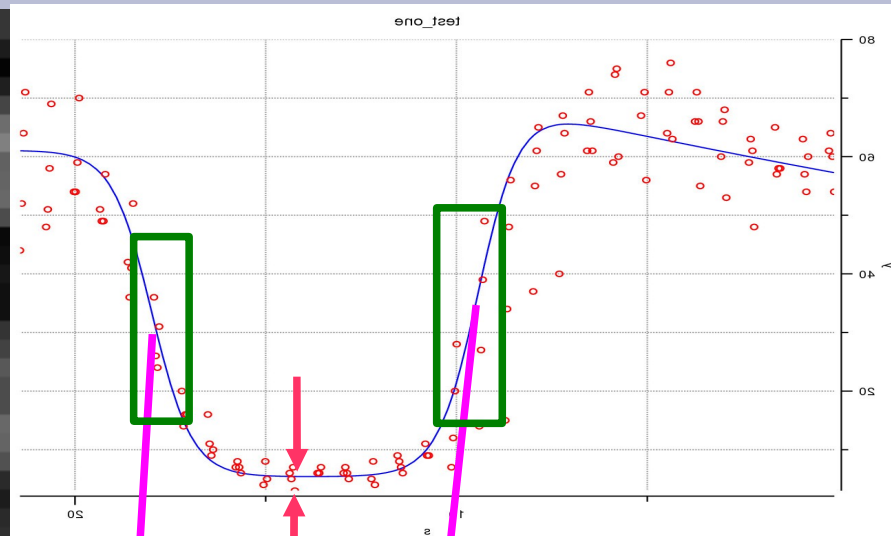


Image Processing Strategy



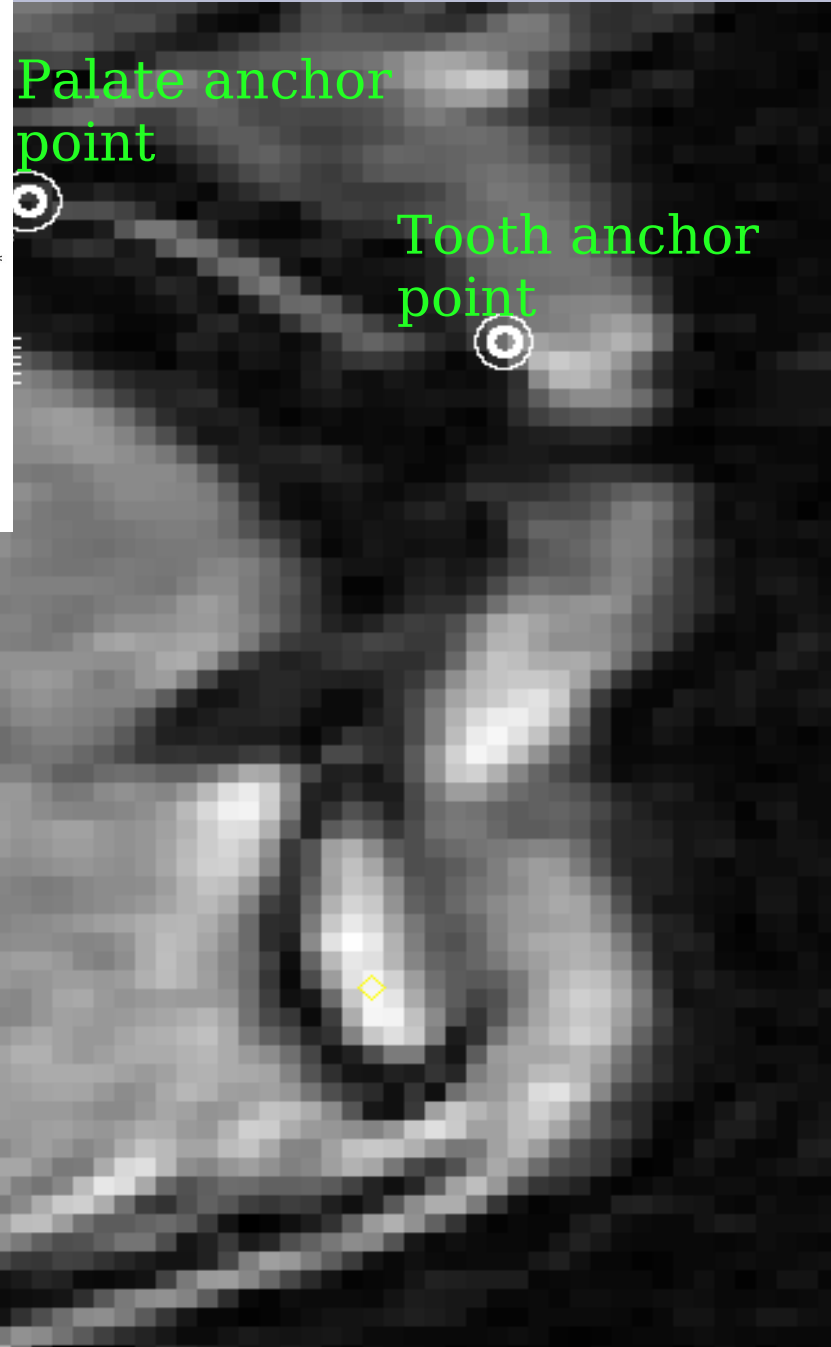
Palate anchor point

Tooth anchor point

Measurement Line

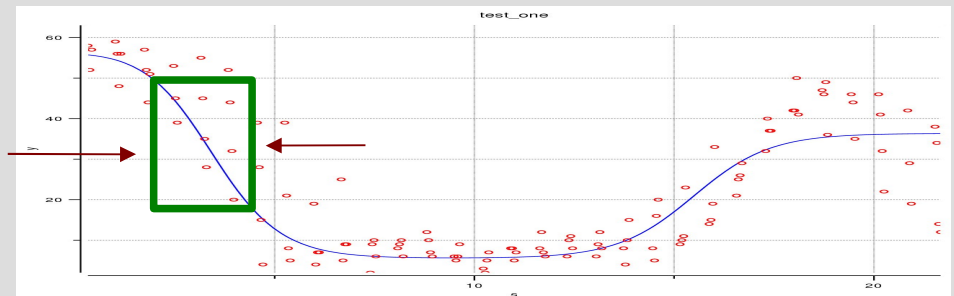
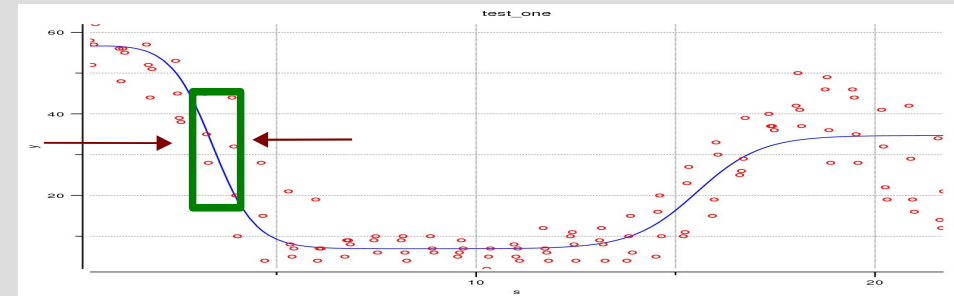
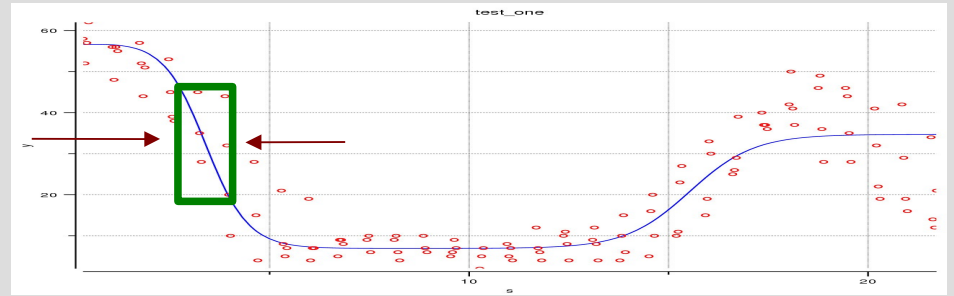
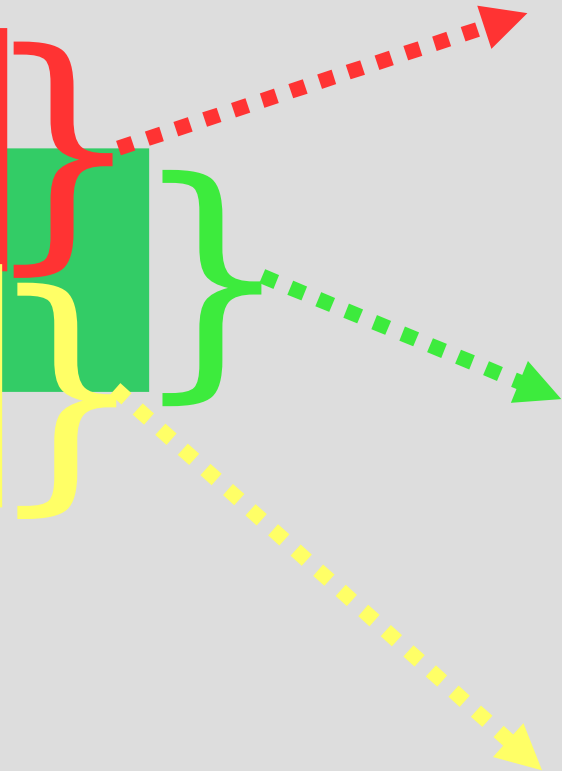
Spinal anchor point and line

✗
✗
✗



Estimating reliability of measurements

Measurement Line

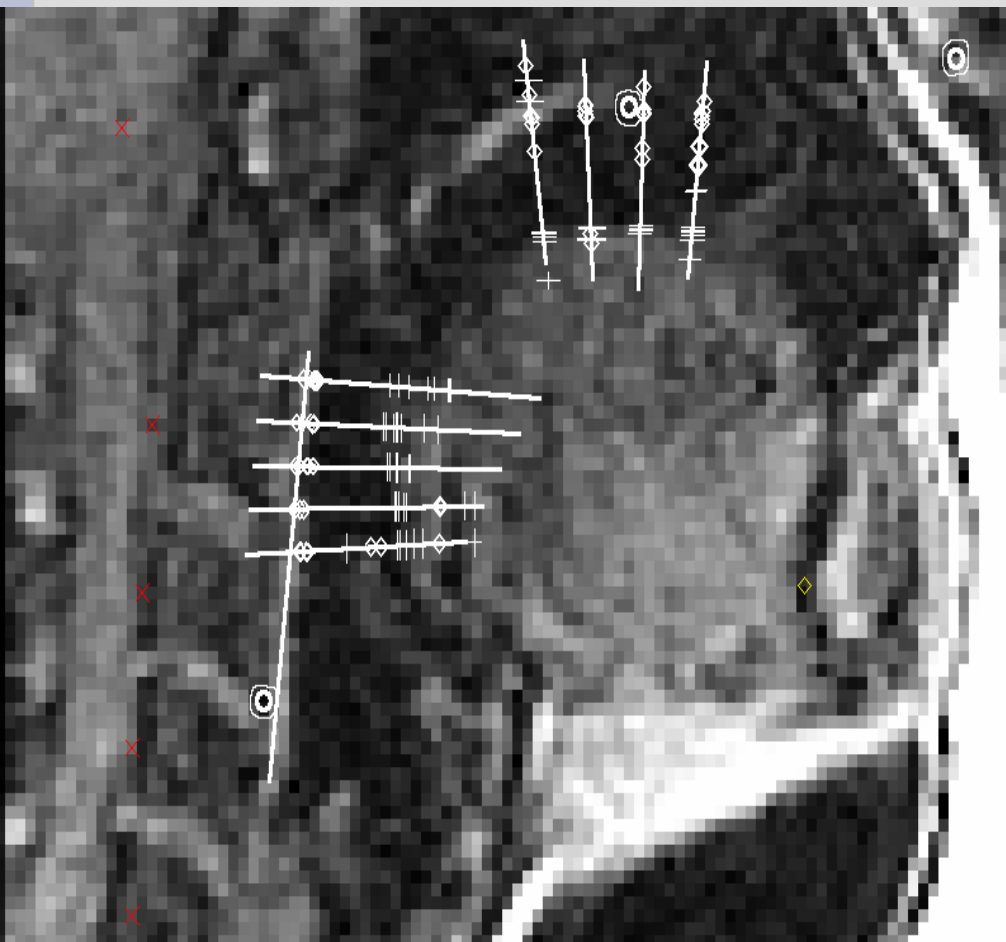


- To get nearly independent estimates:
- shift lines
 - do bootstrap resampling

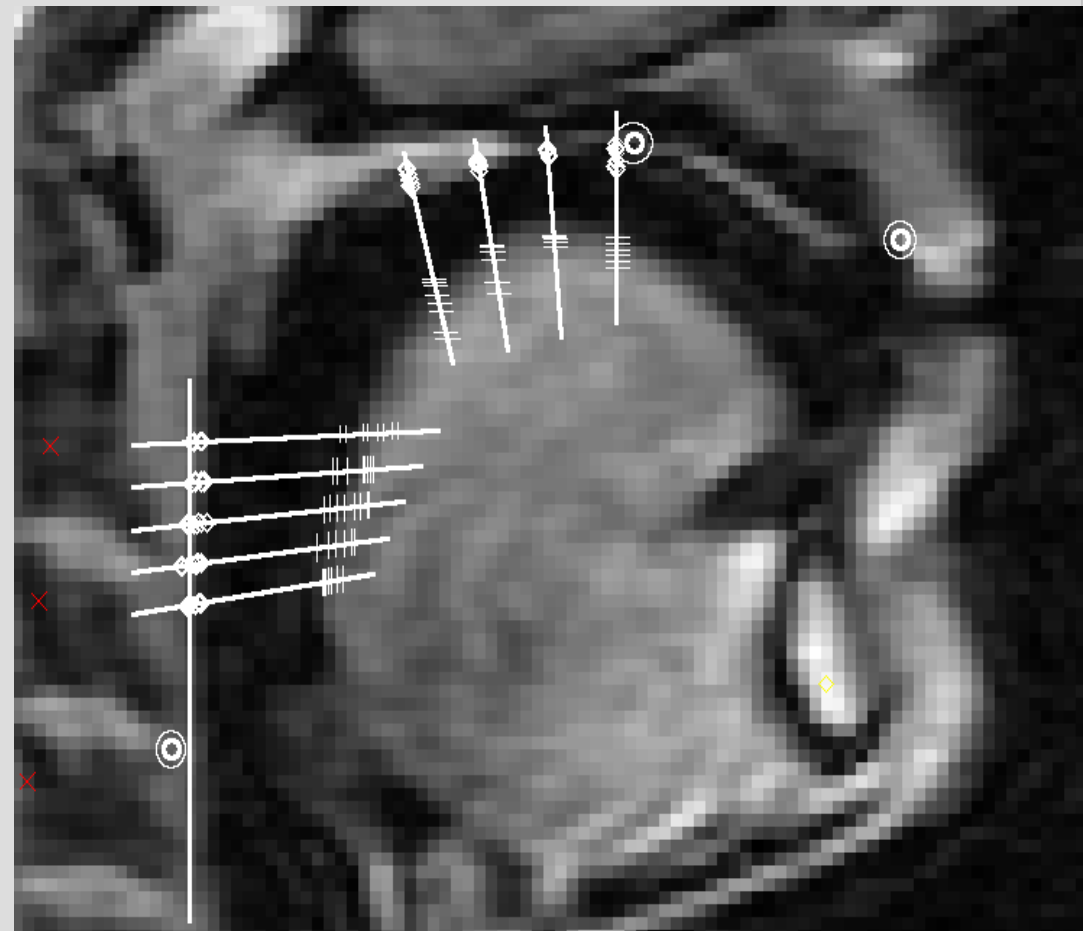
8 samples, up to 2 pixels on each side

Comparison of non-gated and gated reconstructions

Non-gated



Gated



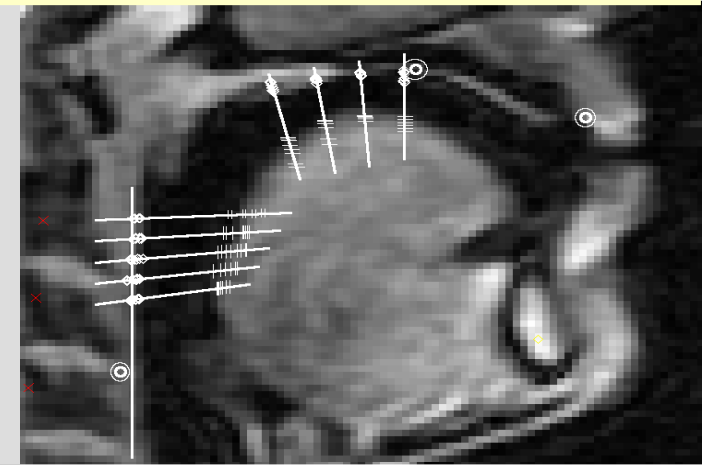
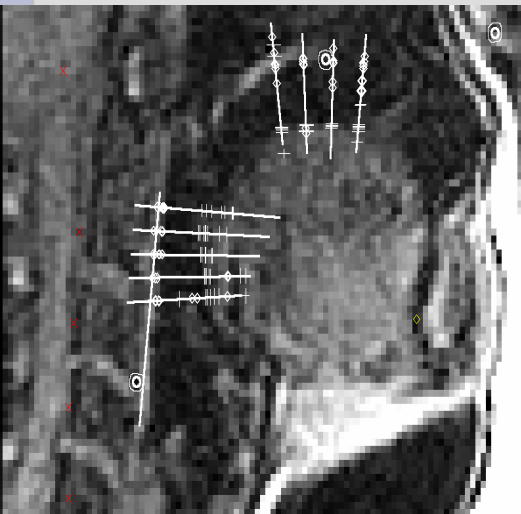
Comparison of non-gated and gated reconstructions

Non-Gated:

- TR / TE = 7.1 ms / Minimum full
- Pulse sequence = Fast Spoiled Gradient Recalled Echo (FSPGR)
- Flip angle = 35 degrees
- Phase / Frequency = 256 / 192
- Matrix = 256 x 256
- Slice thickness = 7mm
- FOV = 36 cm
- NEX = 0.5
- User options = Flow compensation, Sequential acquisition, Extended Dynamic range, Fast Multi
- Phases per location = 440
- Phase field of view = 0.5
- Display field of view = 35 cm
- Total scan duration = NA
- Time resolution = 0.250 sec

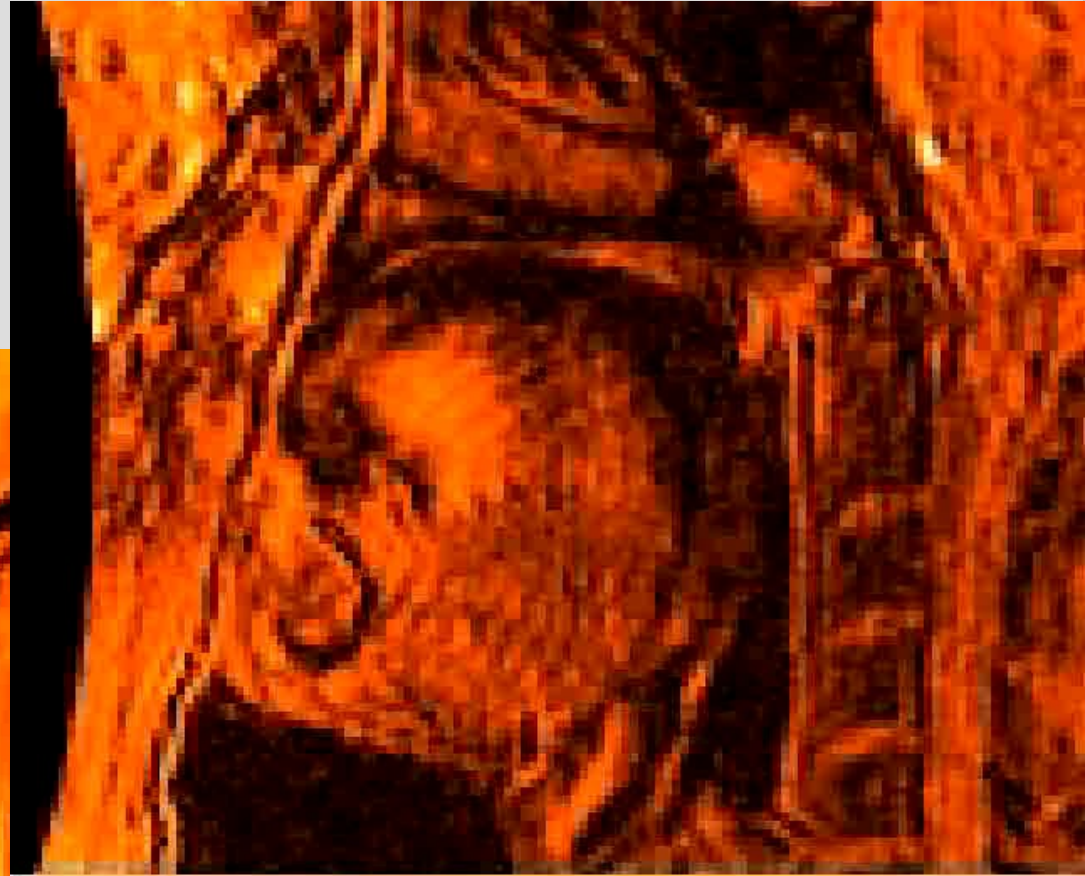
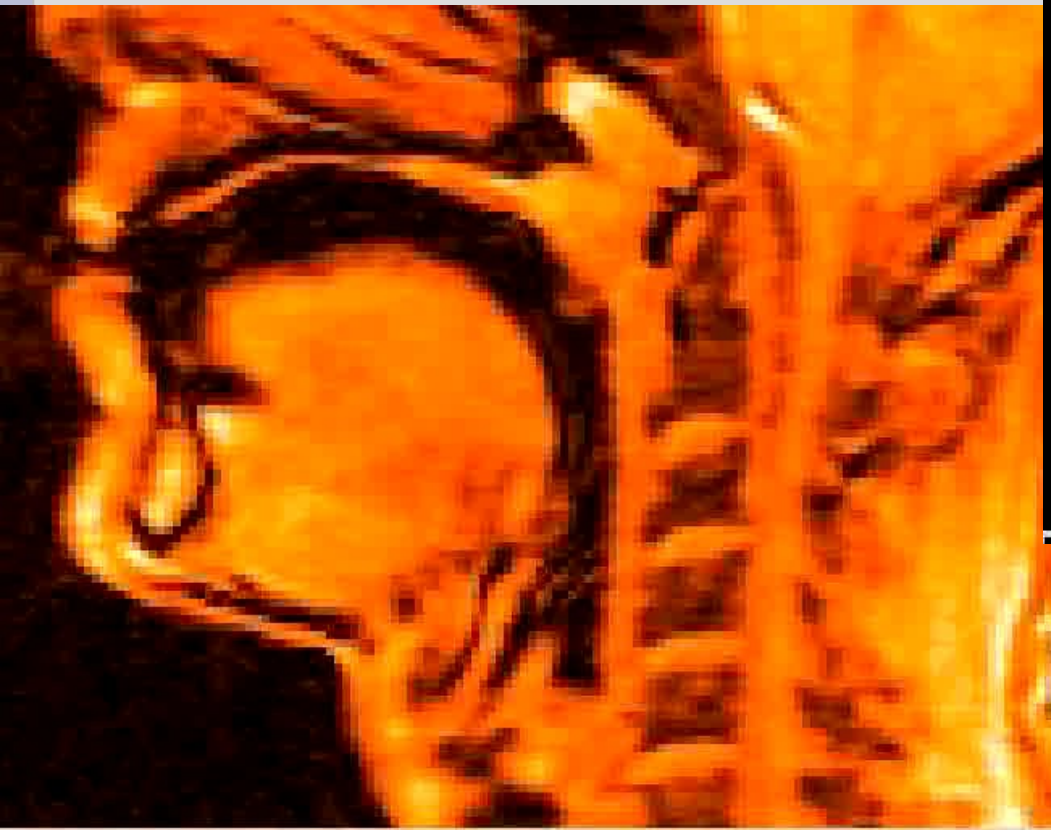
Gated:

- TR / TE = Minimum / Minimum
- Pulse sequence = Fast Spoiled Gradient Recalled Echo (FSPGR)
- Flip angle = 20 degrees
- Phase / Frequency = 256 / 128
- Matrix = 256 x 256
- Slice thickness = 10 mm
- FOV = 36 cm
- NEX = 1
- User options = Flow compensation, Gating, Sequential acquisition, Extended dynamic range
- Trigger type = simulated waveform connected to ECG inputs
- Trigger delay = Minimum (10 ms)
- Gated phases to reconstruct = 20
- Views per segment = 8
- Scanning time = 18 - 20 s
- Number of images per phase = 20
- Time resolution = 0.05 sec

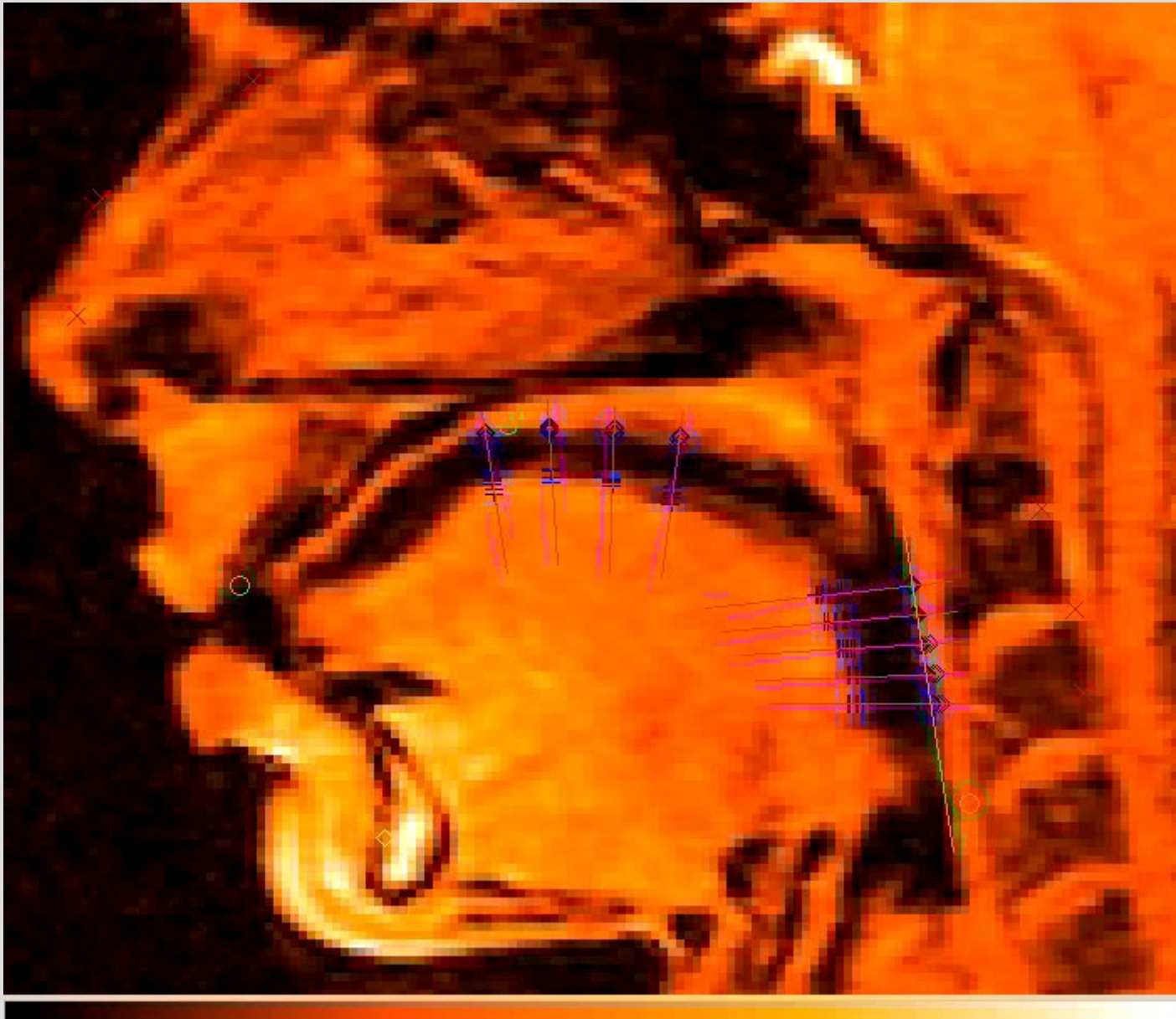


Comparison of ciné sequences

Sequences displayed at 62.5% of real-time.

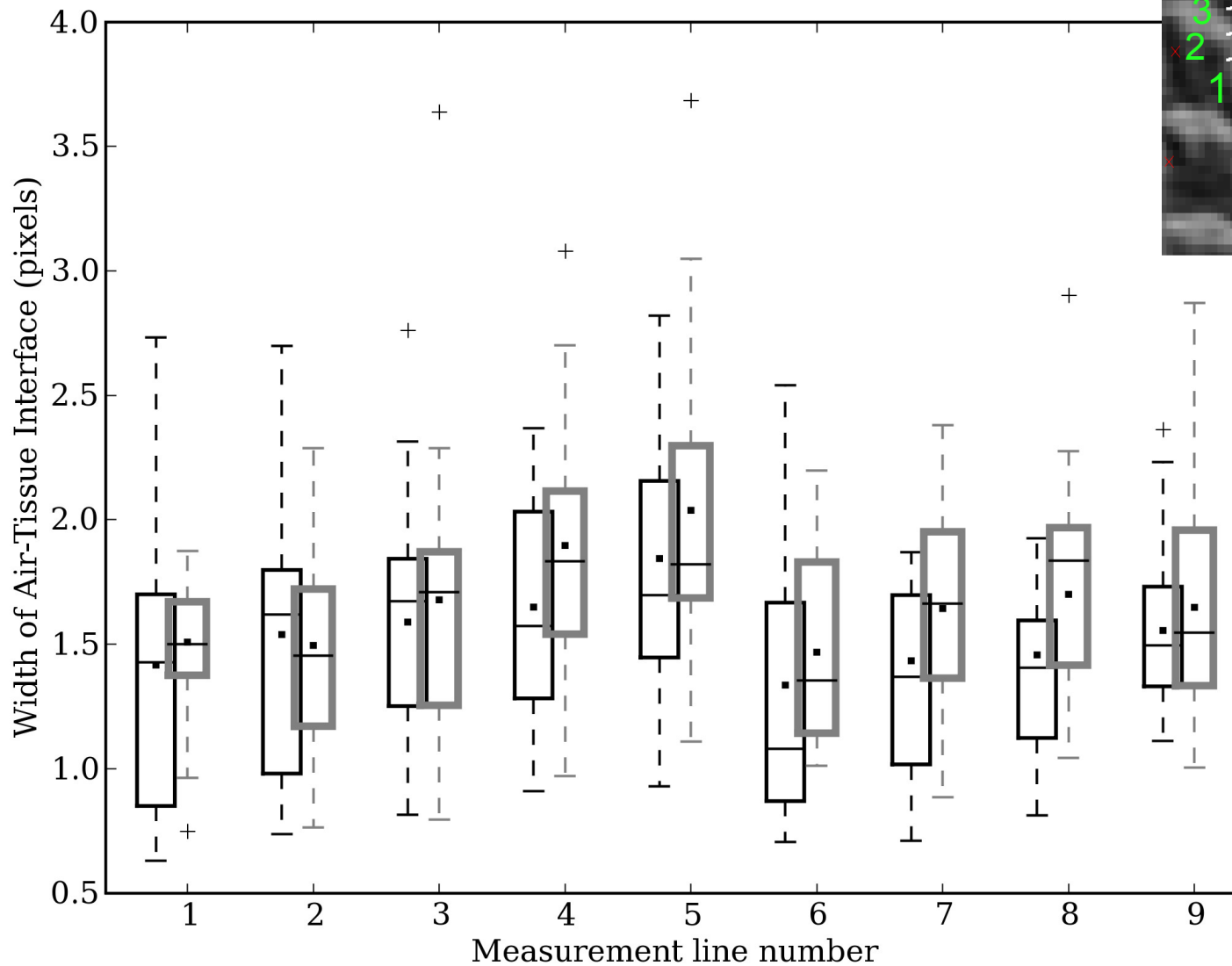
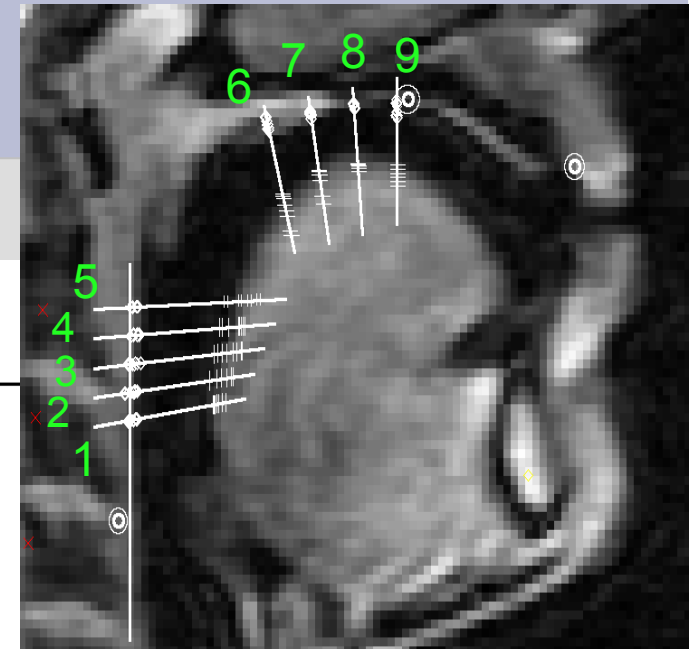


Pushing the gated reconstruction



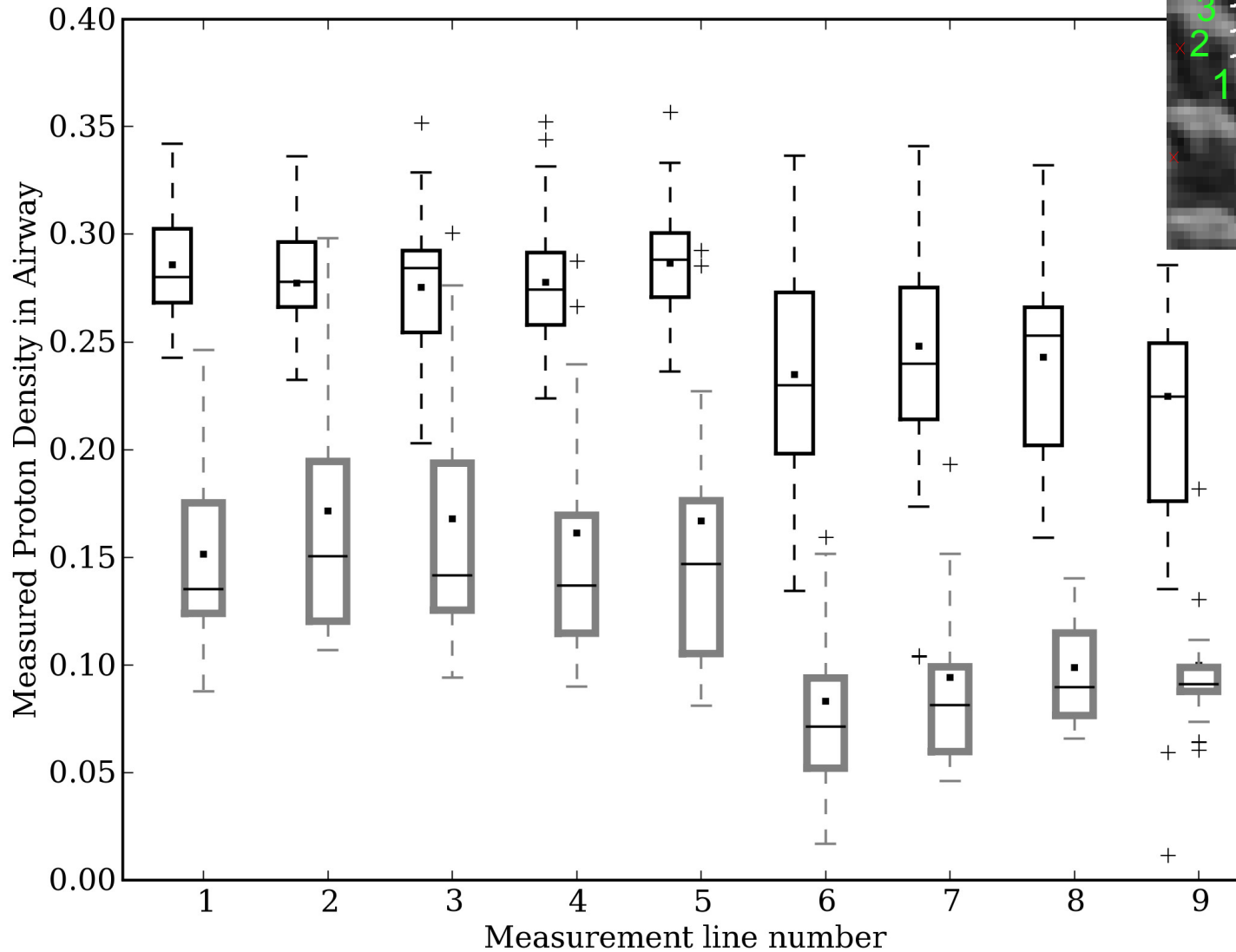
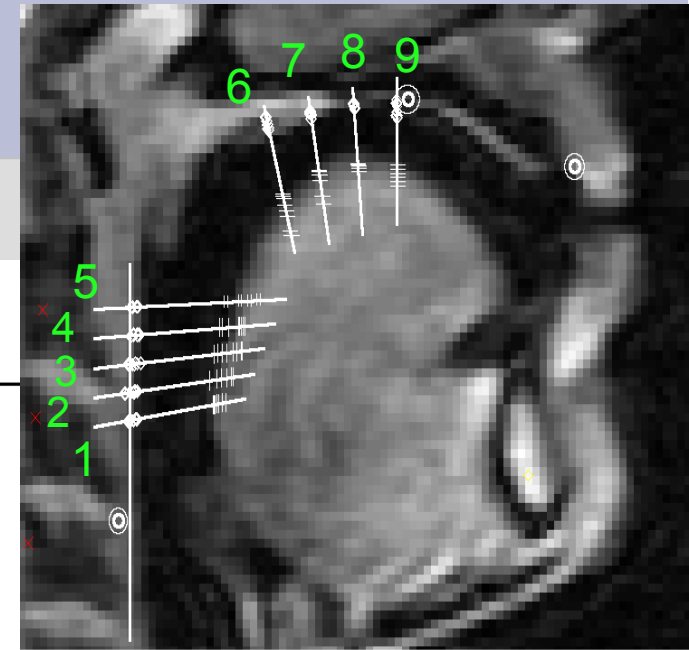
60 images per phase
displayed at 42%
of real-time

Quantitative comparison – spatial resolution



Gated and non-gated are similar (less than $\frac{1}{2}$ pixel difference)

Quantitative comparison – Image smearing into the airway



Gated is much better.

Conclusions

- Gated reconstruction can be much better for imaging voluntary motions:
 - Lower noise
 - Better time resolution
 - Less smearing
 - Similar spatial resolution
- Tongue motions are sufficiently repeatable for gated reconstruction:
 - N=4, true for all subjects with minimal training
 - Recent work: N=15, gated > non-gated for all but 1 or 2
- We suggest that this technique could be used for other voluntary motions:
 - Fingers, jaw, elbows?
 - Studies of joint diseases?

This talk was presented 26 June 2008,
at the 22nd International Congress and Exhibition
of Computer Assisted Radiology and Surgery,
in Barcelona at the Hotel Constanza from June 25 to 28, 2008.
See <http://kochanski.org/gpk/papers/2008/CarsTalk.html> for the abstract
and <http://kochanski.org/gpk/papers/2008/CarsTalk.pdf> for this set of slides.

Image quality in non-gated versus gated reconstruction of tongue motion using Magnetic Resonance Imaging: A comparison using automated image processing

Greg Kochanski, Christopher Alvey, Christina
Orphanidou, John Coleman, A. McIntyre, and Steven
Golding

University of Oxford Phonetics Laboratory,
Nuffield Department of Surgery, University of Oxford,
and the John Radcliffe Hospital, Oxford, UK.

Image quality in
non-gated vs. gated
reconstruction of tongue motion:
automated image processing

Christopher Alvey, Christina Orphanidou, John Coleman,
A. McIntyre, Steven Golding and Greg Kochanski

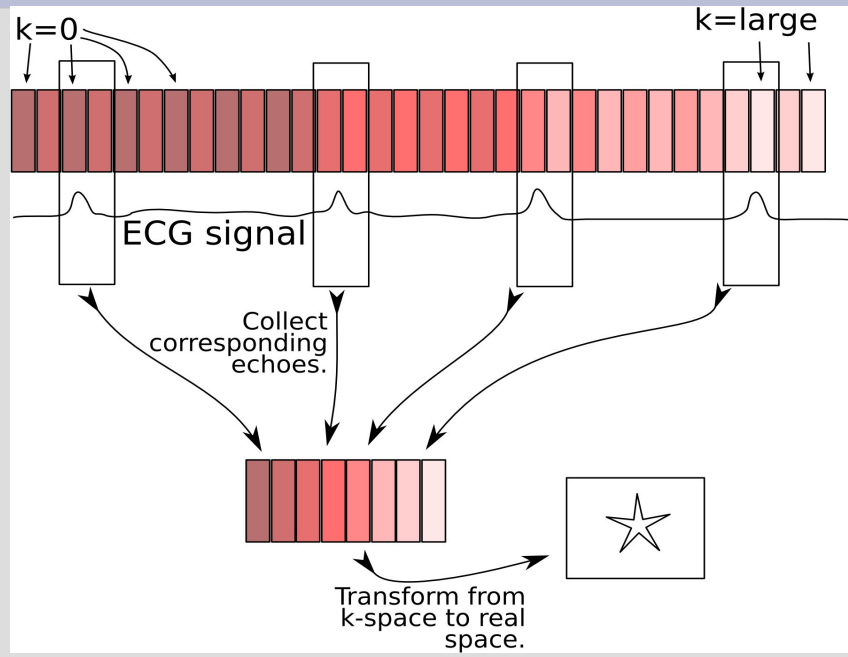
University of Oxford Phonetics Laboratory
Nuffield Department of Surgery, University of Oxford
John Radcliffe NHS Trust

Watching tongues wiggle.

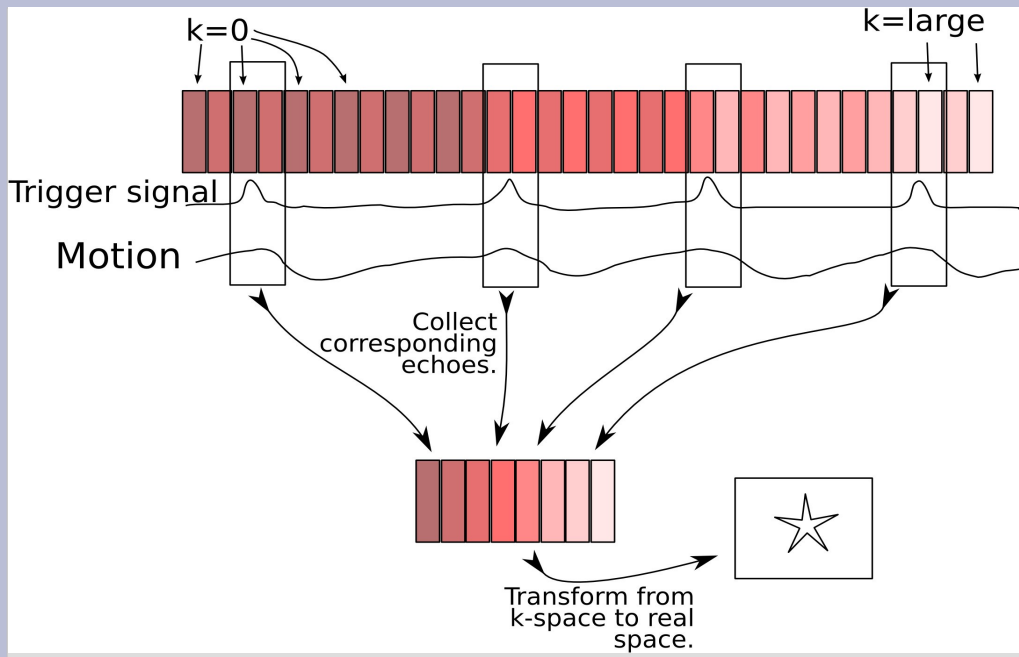
Christopher Alvey, Christina Orphanidou, John Coleman,
A. McIntyre, Steven Golding and Greg Kochanski

University of Oxford Phonetics Laboratory
Nuffield Department of Surgery, University of Oxford
John Radcliffe NHS Trust

Review of gated MRI reconstruction - ideal



Review of gated MRI reconstruction - real



Research Questions

- Are voluntary motions be reproducible enough for gated imaging to work well?
 - Tongue?
- Can we automate image quality assessment?

The apparatus

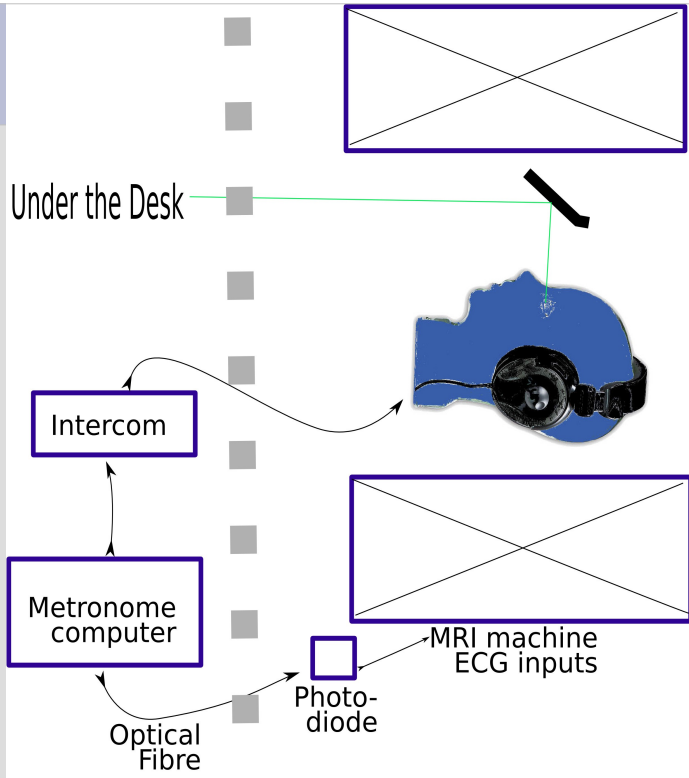


Image Processing Strategy

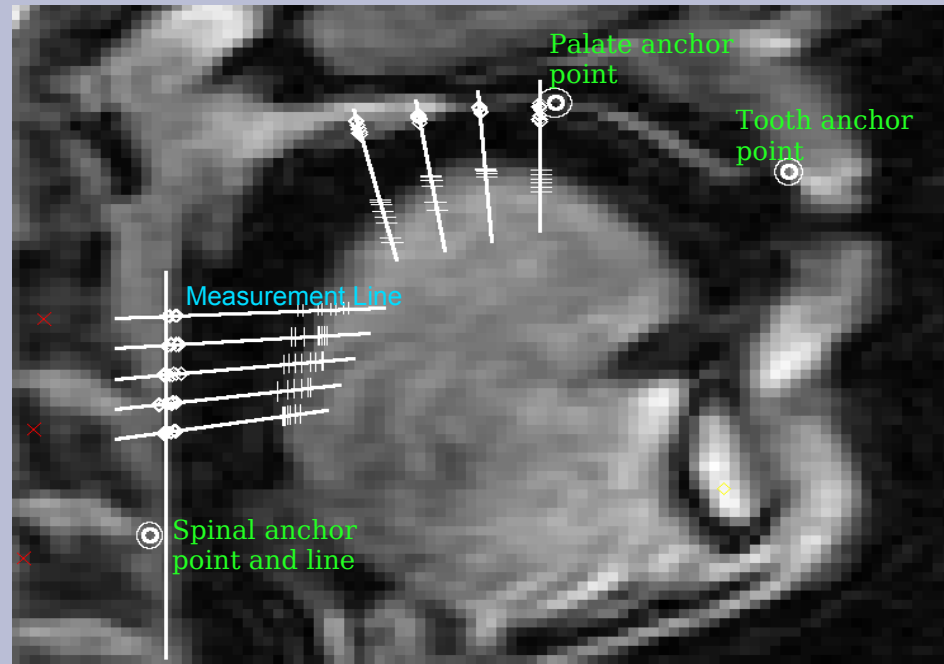
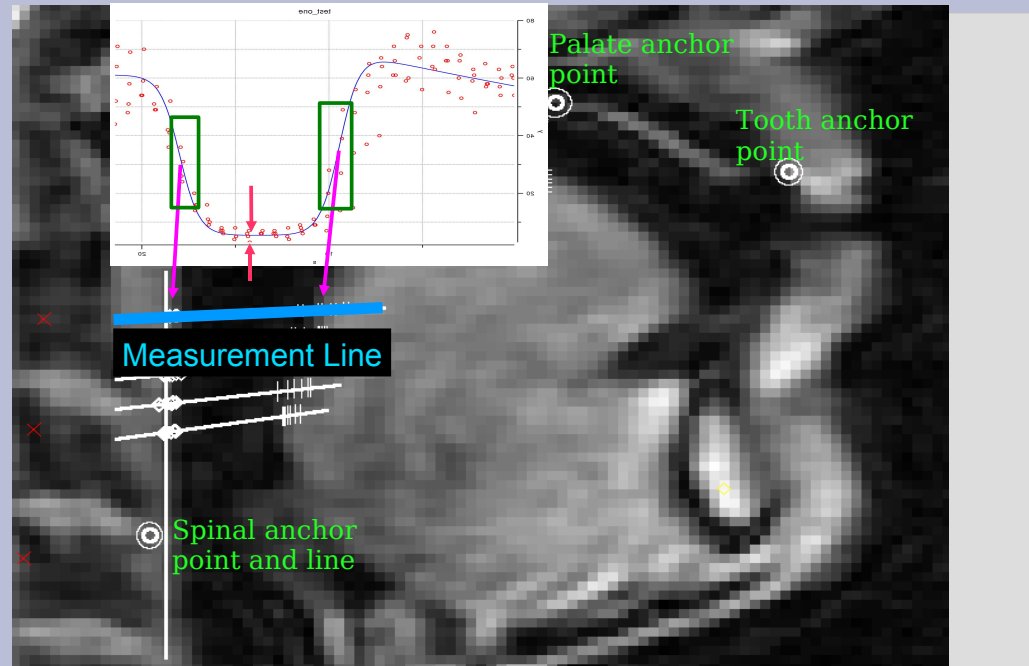


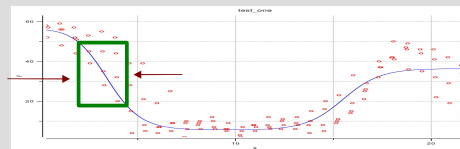
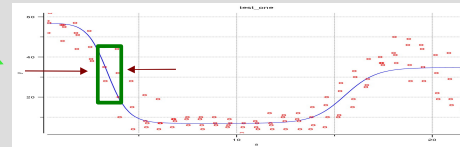
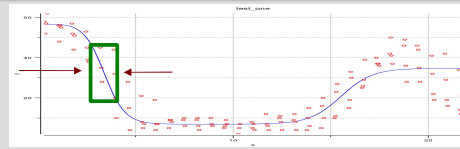
Image Processing Strategy



Estimating reliability of measurements

Measurement Line

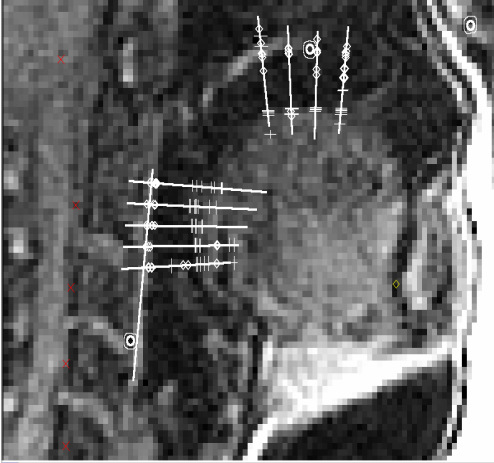
- To get nearly independent estimates:
- shift lines
 - do bootstrap resampling



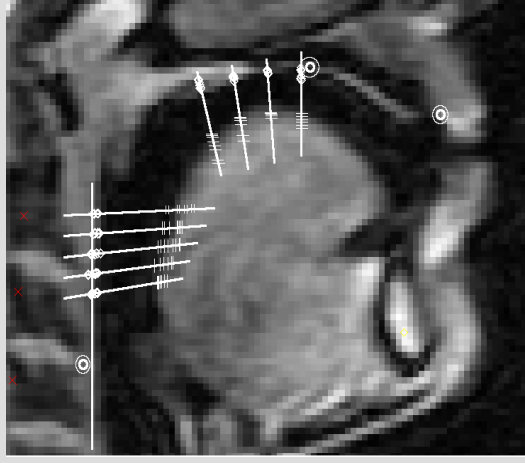
8 samples, up to 2 pixels on each side

Comparison of non-gated and gated reconstructions

Non-gated



Gated



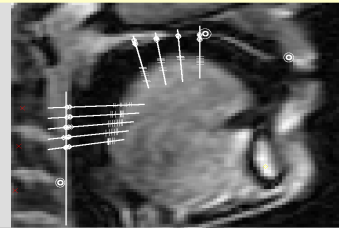
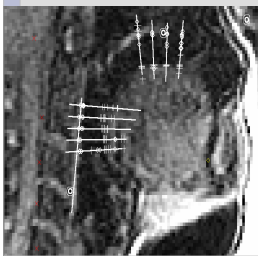
Comparison of non-gated and gated reconstructions

Non-Gated:

- TR / TE = 7.1 ms / Minimum full
- Pulse sequence = Fast Spoiled Gradient Recalled Echo (FSPGR)
- Flip angle = 35 degrees
- Phase / Frequency = 256 / 192
- Matrix = 256 x 256
- Slice thickness = 7mm
- FOV = 36 cm
- NEX = 0.5
- User options = Flow compensation, Sequential acquisition, Extended Dynamic range, Fast Multi
- Phases per location = 440
- Phase field of view = 0.5
- Display field of view = 35 cm
- Total scan duration = NA
- Time resolution = 0.250 sec

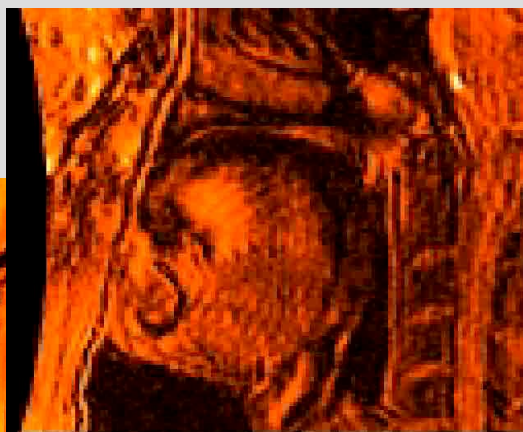
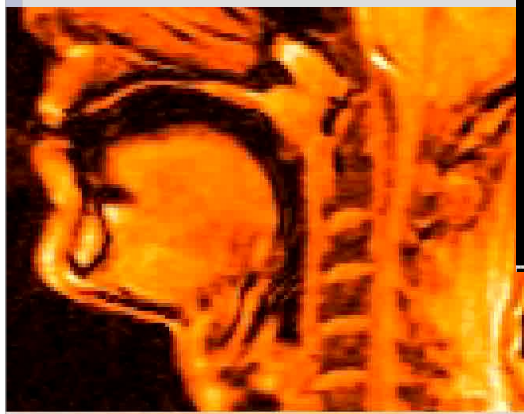Gated:

- TR / TE = Minimum / Minimum
- Pulse sequence = Fast Spoiled Gradient Recalled Echo (FSPGR)
- Flip angle = 20 degrees
- Phase / Frequency = 256 / 128
- Matrix = 256 x 256
- Slice thickness = 10 mm
- FOV = 36 cm
- NEX = 1
- User options = Flow compensation, Gating, Sequential acquisition, Extended dynamic range
- Trigger type = simulated waveform connected to ECG inputs
- Trigger delay = Minimum (10 ms)
- Gated phases to reconstruct = 20
- Views per segment = 8
- Scanning time = 18 – 20 s
- Number of images per phase = 20
- Time resolution = 0.05 sec

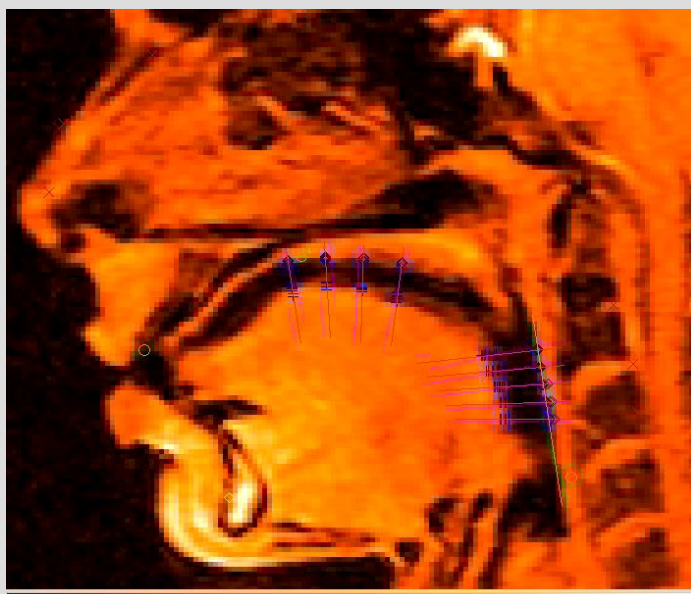

Comparison of ciné sequences

Sequences displayed at 62.5% of real-time.

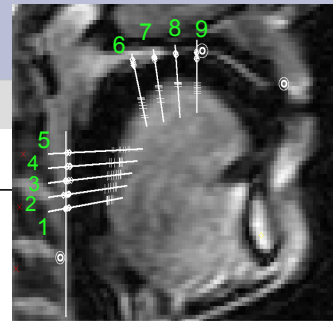
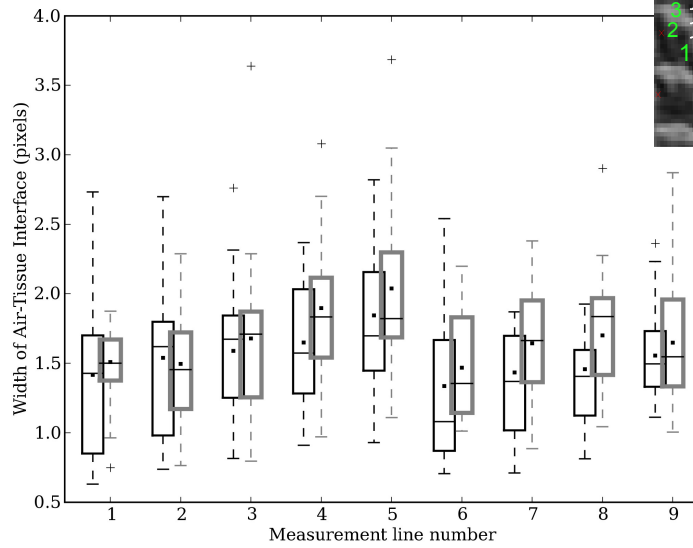


Pushing the gated reconstruction



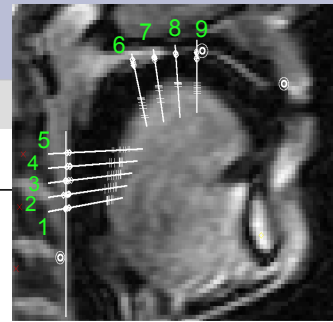
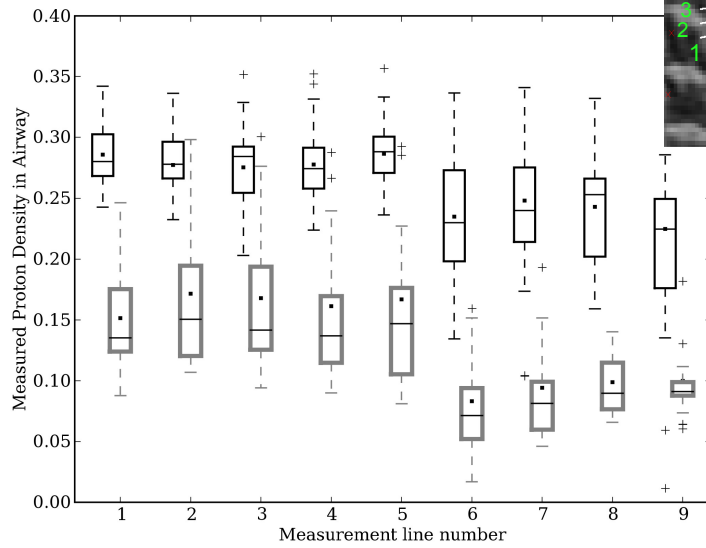
60 images per phase
displayed at 42%
of real-time

Quantitative comparison – spatial resolution



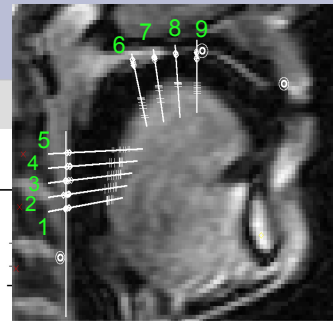
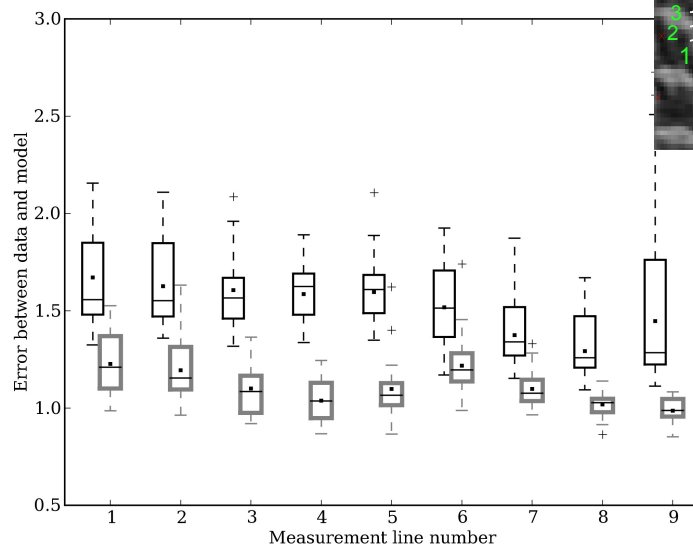
Gated and non-gated are similar (less than $\frac{1}{2}$ pixel difference)

Quantitative comparison – Image smearing into the airway



Gated is much better.

Quantitative comparison – Fit of MRI signal to model



Gated is better.

Conclusions

- Gated reconstruction can be much better for imaging voluntary motions:
 - Lower noise
 - Better time resolution
 - Less smearing
 - Similar spatial resolution
- Tongue motions are sufficiently repeatable for gated reconstruction:
 - N=4, true for all subjects with minimal training
 - Recent work: N=15, gated > non-gated for all but 1 or 2
- We suggest that this technique could be used for other voluntary motions:
 - Fingers, jaw, elbows?
 - Studies of joint diseases?